



Evidence for avoiding the biopsy of typical fibroadenomas in women aged 25–29 years



K. Taylor^{a,*}, S. Lowes^b, E. Stanley^c, P. Hamilton^b, A. Redman^b, A. Leaver^b,
C. Smith^c, R. Lakshman^a, H. Vandersluis^a, M.G. Wallis^a

^a Department of Radiology, Cambridge Breast Unit, Cambridge University Hospitals NHS Foundation Trust, Cambridge Biomedical Campus, Hills Road, Cambridge CB2 0QQ, UK

^b Breast Screening and Assessment Unit, Queen Elizabeth Hospital, Gateshead NE9 6SX, UK

^c Mater Misericordiae University Hospital, Eccles St, Inns Quay, Dublin D07 R2WY, Ireland

ARTICLE INFORMATION

Article history:

Received 15 December 2018

Accepted 26 February 2019

AIM: To determine if any malignancies would have been missed in women aged 25–29 years in the absence of needle biopsy of sonographically typical fibroadenomas, and to present a non-biopsy protocol for fibroadenomas in this age group using strict criteria.

MATERIALS AND METHODS: Women aged 25–29 years undergoing needle biopsies in three centres over a collective 16-year period were identified. Imaging, clinical information, needle biopsy, and surgical histopathology results were obtained from hospital medical records at each centre.

RESULTS: Between January 2001 and December 2016, 885 women aged 25–29 years underwent core biopsy. Of 595 sonographically typical fibroadenomas, 549 were histologically confirmed fibroadenomas, 46 were other benign entities, none were cancers. All cancers were scored as indeterminate or suspicious on ultrasound. With a non-biopsy protocol in clinical practice in Centre A, between 2009 and 2018, 259 sonographically typical fibroadenomas met criteria for non-biopsy, and to date, no cancers have been missed.

CONCLUSION: This study provides evidence for safe non-biopsy of typical fibroadenomas in women aged 25–29 years when the clinical and sonographic presentations meet strict criteria. A protocol for non-biopsy to include this age group is suggested on incorporation of these results into existing guidance for managing younger women.

© 2019 Published by Elsevier Ltd on behalf of The Royal College of Radiologists.

Introduction

Fibroadenomas are the commonest pathological cause of breast lumps in women <30 years and the reason for many

of the referrals made to the breast clinic for this age group.¹ Women in this age group presenting with breast lumps typically undergo a clinical examination and ultrasound imaging in the first instance. Mammography is not routinely performed because of the radiation dose and decreased sensitivity due to the dense breast tissue in young women.² In women <25 years, studies have shown that the risk of malignancy is essentially zero for a mass that is clinically benign and has the ultrasound appearances of a typical fibroadenoma according to criteria initially

* Guarantor and correspondent: K. Taylor, Department of Radiology, Cambridge Breast Unit, Cambridge University Hospitals NHS Foundation Trust, Cambridge Biomedical Campus, Hills Road, Cambridge CB2 0QQ, UK. Tel.: +44 01223 217627.

E-mail address: kathryn.taylor@addenbrookes.nhs.uk (K. Taylor).

described by Stavros and others (wider than tall, well defined with smooth edges or fewer than four gentle lobulations, surrounded by a thin echogenic pseudo-capsule and with no suspicious features), and more recently by Maxwell and Pearson, who refined the imaging criteria and incorporated specific clinical features^{3,4} (Figs 1 and 2). Current recommendations in the UK and Ireland are that women <25 years with a sonographically typical fibroadenoma are discharged without the need for needle biopsy or follow-up.⁵

The incidence of breast cancer increases with age; from 2013–2015 the UK incidence rate was 1 per 100,000 in females aged 20–24 years, rising to 2,754 per 100,000 in females aged 40–44 years.⁶ Although the incidence of breast cancers is low in young women, when diagnosed they are often high grade and aggressive, growing quickly, and may display benign-type ultrasound appearances.⁷ Because of this, caution has been exercised in disregarding sonographically typical fibroadenomas in women >25-years old, and the insufficient published evidence surrounding women in this age group presenting with ultrasound features typical for a fibroadenoma means that current guidance advocates needle biopsy in these cases.⁸

The purpose of this multicentre review was to analyse a total of 16 years of retrospective data investigating lesion pathology in women aged 25–29 years with benign findings on breast examination and ultrasound to determine if any malignancies would have been missed in the absence of needle biopsy. In addition, we present the development of a protocol for non-biopsy of fibroadenomas in women under 30 years old and in the presence of strict sonographic and clinical criteria, with the results of a 9-year audit of its implementation into clinical practice.

Materials and methods

Centre A undertook a retrospective review of all women aged <30 years presenting to their department with ultrasound features typical of a fibroadenoma between January

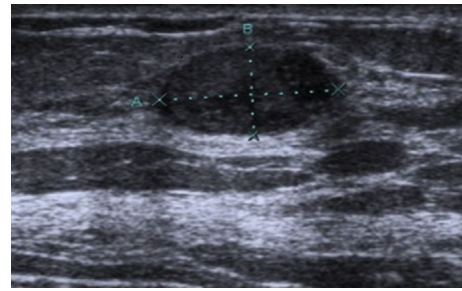


Figure 2 A solid mass lesion with ultrasound appearances of a typical fibroadenoma negating the need for needle biopsy.

2001 and January 2009. Examinations were undertaken by one of six consultant radiologists, a senior registrar training in breast radiology, or an advanced practitioner radiographer. Centre A then established a theoretical incidence of a benign presentation of a breast cancer to their breast unit by looking at three variables: the incidence of breast cancer in women <30 years old, the likelihood of a mass with sonographic features of a fibroadenoma being a cancer on needle biopsy, and if such masses did not undergo needle biopsy, whether any cancers would be missed. Using national and local statistics for breast cancer incidence, applying Stavros' established benign sonographic appearances together with his ultrasound false-negative rate for this group, the risk of malignancy was estimated in women aged 25–29 years.^{3,9}

Results from the theoretical work and retrospective review were used to devise a non-biopsy protocol for masses presenting sonographically as typical fibroadenomas in women under the age of 30 years, i.e., raising the maximum age for non-biopsy from 24 to 29 years. This was implemented in clinical practice in February 2009. In February 2018, the management of all women aged 25–29 years attending the department between 1 February 2009 and 1 February 2018 was reviewed and the safety implications of their protocol were assessed. Centres B and C currently follow UK national guidance by needle sampling sonographically typical fibroadenomas in women aged ≥ 25 years. They undertook a retrospective review of women aged 25–29 years presenting to their departments with a sonographically typical fibroadenoma between 25 July 2002 and 25 October 2016 and 1 January 2011 to 31 December 2016, respectively. In Centre B examinations were undertaken by experienced consultant radiologists, with a small number by senior registrars training in breast radiology. In Centre C, examinations were undertaken by one of five consultant radiologists or a radiologist breast fellow. Imaging, clinical information, needle biopsy, and surgical pathology results were obtained at each centre from the hospital electronic medical records, or, where the patients' presentation preceded electronic recording, paper notes. All three centres used 14 G core biopsy as their method of needle sampling and scored clinical and imaging findings using the Royal College of Radiologists' 1–5 scale.¹⁰

In Centres A and B these studies all formed part of registered audits and did not require local ethical committee approval or patient consent. Centre C required and obtained ethical approval from their local research and

Maxwell criteria for non-biopsy of solid breast masses in women <25 years.
• no known risk factors for breast malignancy
• mass not rapidly enlarging
• smooth discrete mobile mass on clinical examination, or lesion impalpable
• well-defined homogeneously isoechoic or mildly hypoechoic solid mass
• less than 3 cm in greatest dimension
• ovoid shape
• aligned parallel to the skin surface
• smooth or gently lobulated contour (two or three lobulations only)
• no microlobulations)
• thin echogenic pseudocapsule
• no calcification
• no acoustic shadowing

Figure 1 Maxwell criteria for non-biopsy of solid masses in women <25 years.

development department. All data were anonymised and collated in Microsoft Excel (2010) for analysis.

Results

Centre A

The theoretical risk of malignancy was estimated in women aged 25–29 years at only ~0.1% (9). Based on this, it would also theoretically take >50 years to see a cancer in a woman <30 years presenting sonographically as a typical fibroadenoma in Centre A (9). The non-biopsy protocol developed following on from theoretical working undertaken is shown in Electronic [Supplementary Material Appendix A](#).

Between January 2001 and January 2009, prior to the introduction of the non-biopsy protocol, 291 needle biopsies were performed on women 25–29 years (Table 1). Of the 291 needle biopsies, 259 (89%) of them exhibited all the ultrasound features typical of a fibroadenoma (Table 2). In addition, the women had no compounding circumstances, i.e., no known increased risk factors for breast malignancy, the mass was smooth, discrete, and mobile on clinical examination, it was not rapidly enlarging, or the lesion was impalpable.

All 259 of those with features deemed typical of a fibroadenoma were confirmed as fibroadenomas on core biopsy. To the authors' knowledge, none of these women were subsequently diagnosed with breast cancer after a mean follow-up period of 4.3 years (range 0.5–8 years); from this sample the risk of a "typical fibroadenoma" being malignant was 0%.

There were 12 lesions that were "probable" fibroadenomas based on clinical and imaging assessment, but were sampled as they were regarded as having one or more atypical features. Of these, nine were benign (B2) on core biopsy (seven fibroadenomas and two other benign lesions), two were benign, but of uncertain malignant potential (B3; one fibroadenoma and one benign phyllodes tumour following surgical excision), and one was a cancer. The remaining 20 lesions were all thought to represent other entities based on sonographic and/or clinical features and were biopsied accordingly. This included eight cancers making a total of nine cancers in this age group, all of which scored U3 or above on ultrasound.

Fig 3 shows examples of indeterminate (U3) lesions that did not meet typical criteria for a fibroadenoma.

Centre B

Between 25 July 2002 and 25 October 2016, 165 needle biopsies were performed on women aged 25–29 years. Two

Table 1

Retrospective audit of needle sampling in 25–29 year old women presenting symptomatically to centres A, B, and C.

Centre	No. of years of retrospective data	No. of biopsies
A	8	291
B	14	163
C	6	429
Total	28	885

Table 2

Results of needle sampling on women aged 25–29 years in centres A, B and C.

Core biopsy result	Centre		
	A	B	C
Total no. of biopsies	291	163	429
No. of typical fibroadenomas	259	68	268
<i>Core biopsy result</i>			
Fibroadenoma	259	57	233
Other benign (B2) lesion	0	11	11
B3 lesion	0	0	24
Malignancy	0	0	0
No. of "probable" fibroadenomas on ultrasound	12	32	51
<i>Core biopsy result</i>			
Fibroadenoma	7	16	33
Other benign (B2) lesion	2	10	5
B3 lesion	2	2	12
Malignancy	1	4	1
No. of other entities on Ultrasound	20	63	110
<i>Core biopsy result</i>			
Benign B2/B3 lesion	12	47	100
Malignancy	8	16	10

patients were excluded because of incomplete data on the sonographic appearance of the lesions (Table 1). Sixty-eight of the remaining 163 (42%) biopsies exhibited all the ultrasound features typical of a fibroadenoma and the women had no compounding circumstances (Table 2). All 68 were confirmed as benign: 57 were fibroadenomas on initial core biopsy, four were fibrosis, two were fibroadenomatoid hyperplasia, two were fibrocystic change, two were sclerosing adenosis, and one was a cellular fibroepithelial lesion (B3), which was subsequently proven to be a fibroadenoma at surgical excision. To the authors' knowledge, none of these

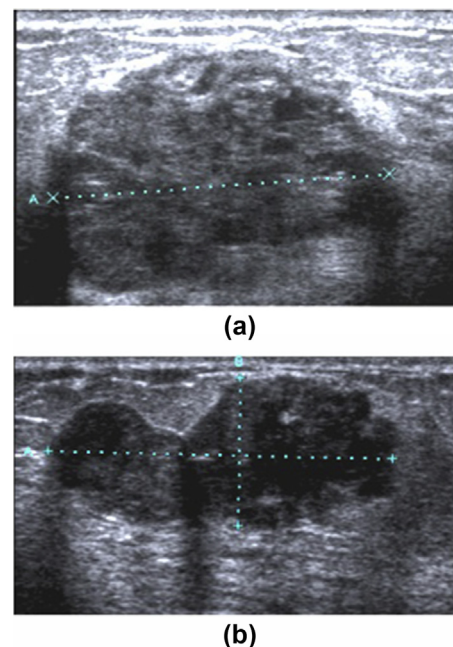


Figure 3 Examples of indeterminate (U3) solid masses presenting in women in the 25–29 age group to Centre A. (a) Cancer in a patient aged 27 years scored as P2/U3. (b) Phyllodes tumour in a patient aged 29 years scored as P3/U3.

women were subsequently diagnosed with breast cancer after a mean follow-up period of 8 years (range 0.5–15.5 years); from this sample the risk of a “typical fibroadenoma” being malignant was 0%.

Thirty-two lesions were “probable” fibroadenomas based on clinical and imaging assessment, but were sampled as they were regarded as having one or more atypical features. Of these, 26 were benign (B2) on core biopsy (16 fibroadenomas and 10 other benign lesions), two were benign but of uncertain malignant potential (B3; both phyllodes tumours, one benign and one “borderline” following surgical excision), and four were malignant (B5; three invasive ductal carcinomas and one infiltrating poorly differentiated carcinoma). The remaining 63 lesions were all thought to represent other entities based on sonographic and/or clinical features and were biopsied accordingly.

In total there were 16 cancers in this age group. All were scored U3 or above on ultrasound except one, which was scored U2 but this lesion was described in the ultrasound report as patchy hypoechoic change (images not available for retrospective review as this pre-dated PACS storage of ultrasound images), and, based on the patient’s age, was thought likely to represent fibrocystic change. Importantly, it did not have the appearance of a fibroadenoma, and therefore, it warranted biopsy. Initial core showed a papilloma with an area suspicious of DCIS (B4) and confirmed at histology as DCIS after surgery.

Centre C

Between 1 January 2011 and 31 December 2016, 429 needle biopsies were performed on women aged 25–29 years (Table 1) with 268 (62%) exhibiting all the ultrasound features typical of a fibroadenoma and the women had no compounding circumstances (Table 2). All 268 were confirmed as benign: 213 were fibroadenomas on initial core biopsy, 31 other benign lesions, 24 were initially B3 on core biopsy but all benign at surgical excision (20 fibroadenomas, one benign phyllodes, one hamartoma, and two benign papillary lesions). To the authors’ knowledge, none of these women were subsequently diagnosed with breast cancer after a mean follow-up period of 5.15 years (range 1.8–6.8 years); from this sample the risk of a “typical fibroadenoma” being malignant was 0%.

There were 51 lesions that were probable fibroadenomas based on clinical and imaging assessment, but they were regarded as having one or more atypical features. Of these, 38 were benign (B2) on core biopsy (33 fibroadenomas and five other benign lesions), 12 were benign but of uncertain malignant potential (B3: five fibroadenomas, two benign phyllodes, and five other benign lesions at surgical excision) and one was malignant. The remaining 110 lesions were all thought to represent other entities based on sonographic and/or clinical features and were biopsied accordingly.

In total there were 11 cancers in this age group. None of the cancers met the sonographic criteria for typical fibroadenomas; however, one lesion was given a U2 score but this lesion was described in the ultrasound report as demonstrating a combination of microlobulations, calcification,

and marked posterior shadowing. Importantly, if the non-biopsy protocol was applied, this would trigger a needle biopsy.

Non biopsy protocol in clinical practice at Centre A in women aged 25–29 years

Between 1 February 2009 and 1 February 2018, with the non-biopsy protocol (Electronic [Supplementary Material Appendix A](#)) in routine clinical practice at Centre A, 551 women aged 25–29 years presented with solid breast lesions. Of these, 366 (66%) had lesions thought most likely to be fibroadenomas and 279 (51%) met the criteria for discharge without needle biopsy. None of the discharged patients was subsequently diagnosed with breast cancer after a mean follow-up period of 4.9 years (range 0.5–9.4 years); from this sample the risk of a “typical fibroadenoma” being malignant was 0%. There were 87 “probable fibroadenomas” that underwent needle sampling as they did not meet all the non-biopsy criteria. Of these, 79 were benign on core biopsy consisting of 77 fibroadenomas and two other benign disease entities. Seven were B3 on core biopsy histology; subsequently, five were confirmed as fibroadenomas and two were benign phyllodes at surgical histology. There were nine cancers diagnosed in women aged 25–29 years during this period. None exhibited the ultrasound appearances typical of a fibroadenoma and all underwent needle biopsy at initial assessment; an example is shown in Fig 4. Fig 5 summarises the non-biopsy protocol in practice.

Discussion

Fibroadenomas are the commonest cause of focal solid mass lesions in women <30 years of age^{3,10} and the investigation and needle biopsy of this benign condition consumes precious healthcare resources in the UK and beyond. The current challenges of increased activity and a reducing workforce mean ways of streamlining services whilst not compromising safety must be embraced.¹¹ In addition, there be a continuing effort not to do harm through unnecessary over investigation of patients. Several studies have quantified the risk of a sonographically benign lesion being malignant as <2% (in patients of all ages).^{9,10,12} In particular, Stavros *et al.* reported a 1.6% ultrasound false-negative rate for 426 solid lesions, which had benign ultrasound features

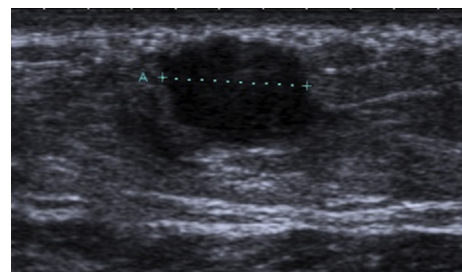


Figure 4 A cancer in a 29-year-old woman with a 4-week history of a lump, 12 weeks pregnant.

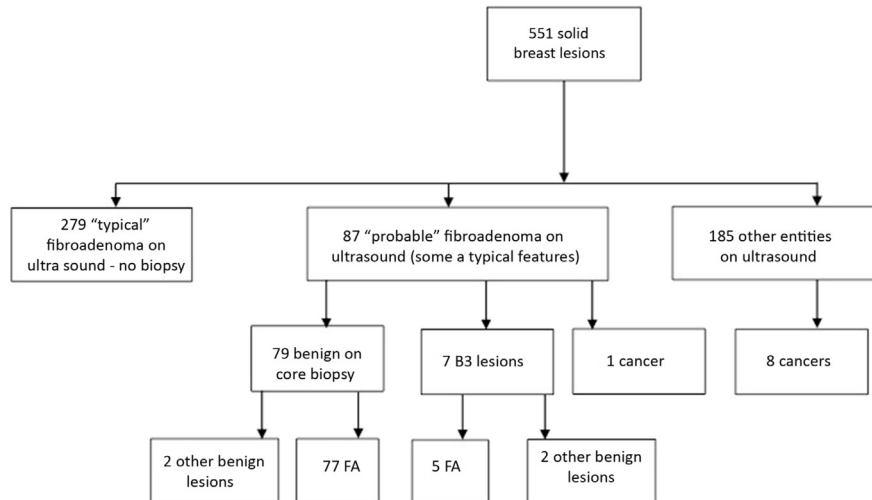


Figure 5 Non-biopsy protocol in clinical practice (Centre A).

(e.g., ellipsoid shape [wider than tall], a well-defined outline with smooth edges or fewer than four gentle lobulations) based on women aged 18–88 years.³

The current UK guidance of not routinely needle sampling women ≤ 25 years with lesions whose ultrasound appearances are of a “typical fibroadenoma” was first proposed by Smith¹³ who identified 357 women with an ultrasound diagnosis of a fibroadenoma over a 10-year period. This group contained three benign phyllodes tumours; two >3 cm in size and one with a history of rapid growth and a single cancer, which on review of the imaging, was considered to have irregular margins and had been misclassified. In the same year Hamilton¹⁴ reviewed the seven cancers diagnosed in women ≤ 25 years between 1987 and 2002 in Nottingham. Of the five that had undergone ultrasound, all were classified as suspicious. They introduced a policy not to biopsy women ≤ 25 years with clinically and sonographically benign findings (according to the Stavros criteria) and reported not having missed a single cancer between 2003 and 2008. O’Neill *et al.* similarly missed no cancers over an 18 month period between January 2011 and June 2012 in a study of 540 patients.¹⁵ Loving *et al.* reported that over the period 2002–2006 the overall rate of malignancy in women <30 years old presenting with focal breast symptoms was 0.4%, and found no cancers amongst palpable lesions that had the ultrasound appearances typical of a fibroadenoma.²

Maxwell and Pearson’s study reviewed 3,334 cancers diagnosed over 17 years. Nine of these cancers were in patients <30 years (one under 25) and none of them would have been missed if their protocol for safely avoiding needle biopsy in typical fibroadenomas had been in place.⁴ They extended the imaging criteria to include clinical features, but so far there has been a reluctance to incorporate women >25 in this practice; the incidence of cancer increases with increasing age and to date there has been little robust evidence to support such a move.

To the authors’ knowledge the present cohort is the largest to provide evidence of safe practice in implementing a non-biopsy protocol in 25–29-year-old women meeting

strict criteria. In the present current study, over 800 cases between three centres have been audited retrospectively, and using the Maxwell criteria, would not have missed any cancers in the 25–29 year age group. Furthermore, Centre A demonstrates 9 years of successfully using a non-biopsy protocol in clinical practice with no cancers missed. Interestingly, even prior to the introduction of the non-biopsy protocol a much higher percentage of the biopsied lesions at Centre A were classified sonographically as “typical” fibroadenomas compared to the other two sites (89% of lesions were “typical” fibroadenomas in Centre A versus 42% in Centre B and 62% in Centre C). The exact reason for this is unclear, but one reason may be that Centre A had a lower proportion of lesions classified as “probable” versus “typical” fibroadenomas compared to the other two sites; 4% of all sonographically fibroadenoma-like lesions in Centre A were classified as “probable”, versus 32% in Centre B and 16% in Centre C. Another possibility is a higher threshold for needle sampling other benign entities in Centre A versus the other two sites; 7% of total biopsies in Centre A were deemed on ultrasound as benign lesions other than fibroadenomas, versus 38% in Centre B and 26% in Centre C. Despite Centre C having the largest number of sonographically typical fibroadenomas assigned B3 on core biopsy (24 versus zero in Centres A and B), all were ultimately benign at surgical excision (20/24 were confirmed as fibroadenomas), and this likely reflects variations in local pathology reporting practices.

In addition to the possibility of missing cancers, adopting a non-biopsy, non-follow-up policy might also raise anxiety about missing phyllodes tumours. These are rarer than breast cancer and have a median age of presentation 20 years older than fibroadenomas. When malignant they usually present as rapidly growing masses, and although it is not easy to differentiate benign phyllodes tumours from fibroadenomas, the malignant ones usually have different characteristics.¹⁶ Maxwell and Pearson found seven phyllodes tumours (three in women <25 years); only one, in a 25-year-old, would have been missed, but it had increased in size over 6 months and was benign on subsequent

surgical histology. The present results also include phyllodes tumours. The non-biopsy protocol used by centre A includes “suspected phyllodes” as an indication to proceed to needle biopsy, the inference being a rapidly increasing size. Centre B has incorporated Maxwell’s specific size criteria for non-biopsy (<3 cm in greatest dimension), and it seems prudent to carry this forward for inclusion in any future guidelines for non-biopsy in women <30 years (Electronic Supplementary Material Appendix B). In addition, for safe implementation of such a non-biopsy protocol, certain precautions are required. Women must only be discharged if they meet all the protocol criteria, i.e., their lesion does not appear suspicious clinically, has all the ultrasound appearances typical of a fibroadenoma, and they do not have any compounding circumstances (e.g., family history, genetic predisposition). Adherence to this must be strict. As always, all women who are discharged without follow-up should be encouraged to examine their breasts regularly and return if they detect any changes including increase in lesion size.

There are certain limitations of the present study. None of the women discharged without biopsy have subsequently been diagnosed with breast cancer within the three centres; however, it is acknowledged that the possibility of small numbers being lost to follow-up in other centres.

All previous studies quantifying the risk of malignancy of a “typical fibroadenoma” in specific age groups have used small sample sizes^{2,3,11,17–19} whereas the present study with collation of data from multiple centres allows a more accurate quantification of malignancy risk. Any limitations in calculating the theoretical rate of malignancy are largely (if not completely) mitigated by the actual clinical data presented from the three sites.

Elastography was not routinely used during this audit period and it is recognised that its addition may increase certainty in assigning a lesion as a fibroadenoma meeting the criteria not to biopsy.

In conclusion, this study provides evidence for safe non-biopsy of typical fibroadenomas in women 25–29 years when clinical and sonographic features meet strict criteria. Incorporating results into existing guidance for managing younger women, a protocol for non-biopsy to include this age group is suggested.

Conflict of interest

The authors declare no conflict of interest.

Appendix A. Supplementary data

Supplementary data to this article can be found online at <https://doi.org/10.1016/j.crad.2019.02.019>.

References

- Harvey JA, Nicholson BT, LoRusso AP, et al. Short-term follow-up of palpable breast lesions with benign imaging features: evaluation of 375 lesions in 320 women. *AJR Am J Roentgenol* 2009;**193**:1723–30.
- Loving VA, DeMartini WB, Eby PR, et al. Targeted ultrasound in women younger than 30 years with focal breast signs or symptoms: outcomes analyses and management implications. *AJR Am J Roentgenol* 2010;**195**:1472–7.
- Stavros AT, Thickman D, Rapp CL, et al. Solid breast nodules: use of sonography to distinguish between benign and malignant lesions. *Radiology* 1995;**196**:123–34.
- Maxwell AJ, Pearson JM. Criteria for the safe avoidance of needle sampling in young women with solid breast masses. *Clin Radiol* 2010;**65**:218–22.
- Willett AM, Michell MJ, Lee MJR, editors. *Best practice diagnostic guidelines for patients presenting with breast symptoms*. Department of Health; 2010. Available at: <http://www.associationofbreastsurgery.org.uk/Content/Guidelines.aspx>. [Accessed 5 July 2018].
- Cancer research UK. Breast cancer incidence (invasive) statistics. Available at: <https://www.cancerresearchuk.org/health-professional/cancer-statistics/statistics-by-cancer-type/breast-cancer/incidence-invasive#heading-One>. [Accessed 5 July 2018].
- Skaane P, Engedal K. Analysis of sonographic features in the differentiation of fibroadenoma and invasive ductal carcinoma. *AJR Am J Roentgenol* 1998;**170**:109–14.
- Dall BJG. Ultrasound diagnosis of fibroadenoma. Is biopsy always necessary? *Clin Radiol* 2008;**63**:516–7.
- Taylor K, Britton P, Sonoda L, et al. Is it safe not to biopsy fibroadenomas in women under 30? *Breast Cancer Res* 2009;(Suppl. 2):11. P1. Poster BSBR 2009.
- Maxwell AJ, Ridley NT, Rubin G, et al. The royal College of radiologists breast group breast imaging classification. *Clin Radiol* 2009;**64**:624–7.
- The breast imaging and diagnostic workforce in the United Kingdom: results of a survey of NHS Breast Screening Programme units and radiology departments*. London: The Royal College of Radiologists; 2016. Available at: https://www.rcr.ac.uk/system/files/publication/field_publication_files/bfcr162_bsbr_survey.pdf. [Accessed 18 July 2018].
- Mendelson EB, Böhm-Vélez M, Berg WA, et al. ACR BI-RADS® ultrasound. In: *ACR BI-RADS® atlas, breast imaging Reporting and data system*. Reston, VA: American College of Radiology; 2013.
- Smith G, Burrows P. Ultrasound diagnosis of fibroadenoma, is biopsy always necessary? *Clin Radiol* 2008;**63**:511–5.
- Hamilton L, Evans A, Cornford E, et al. Ultrasound diagnosis of fibroadenoma—is biopsy always necessary? *Clin Radiol* 2008;**63**:1070–1.
- O'Neill A, Hargaden G, Flanagan F, et al. A retrospective audit of breast biopsy in patients under 25 years. Can we avoid breast biopsy in these patients with probable fibroadenomas on imaging?. ECR; 2014, <https://doi.org/10.1594/ecr2014/C-1952>. [Accessed 16 July 2018].
- Zonderland HM, Pope TL, Nieborg AJ. The positive predictive value of the breast imaging reporting and data system (BI-RADS) as a method of quality assessment in breast imaging in a hospital population. *Eur Radiol* 2004;**14**:1743–50.
- Wallis M, Tarvidon A, Helbich T, et al. Guidelines from the European Society of Breast Imaging for diagnostic interventional breast procedures. *Eur Radiol* 2007;**17**:581–8.
- Graf O, Helbich TH, Hopf GG, et al. Probably benign breast masses at US: is follow-up an acceptable alternative to biopsy? *Radiology* 2007;**244**:87–93.
- Taylor K, Britton P, O’Keeffe S, et al. Quantification of the UK 5-point breast imaging classification and mapping to BI-RADS to facilitate comparison with international literature. *Br J Radiol* 2011;**84**:1005–10.