

Received:  
15 March 2022

Accepted:  
11 July 2022

Published online:  
25 July 2022

© 2022 The Authors. Published by the British Institute of Radiology under the terms of the Creative Commons Attribution-NonCommercial 4.0 Unported License <http://creativecommons.org/licenses/by-nc/4.0/>, which permits unrestricted non-commercial reuse, provided the original author and source are credited.

Cite this article as:

Healy NA, Parag Y, Soppelsa G, Wignarajah P, Benson JR, Agrawal A, et al. Does pre-operative breast MRI have an impact on surgical outcomes in high-grade DCIS?. *Br J Radiol* (2022) 10.1259/bjr.20220306.

## FULL PAPER

# Does pre-operative breast MRI have an impact on surgical outcomes in high-grade DCIS?

<sup>1</sup>NUALA A. HEALY, <sup>1</sup>YETHIKSHA PARAG, <sup>1</sup>GIORGIA SOPPELSA, <sup>1</sup>PRIMEE WIGNARAJAH, <sup>1</sup>JOHN R. BENSON, <sup>1</sup>AMIT AGRAWAL, <sup>1</sup>PARTO FOROUHI, <sup>1</sup>FLEUR KILBURN-TOPPIN and <sup>2</sup>FIONA J. GILBERT

<sup>1</sup>Cambridge Breast Unit, Cambridge University Hospitals NHS Foundation Trust, Addenbrookes' Hospital, Hills Road, Cambridge, UK

<sup>2</sup>Department of Radiology, University of Cambridge School of Clinical Medicine, Box 218, Level 5, Cambridge Biomedical Campus, Cambridge, UK

Address correspondence to: Fiona J. Gilbert  
E-mail: [fjg28@medschl.cam.ac.uk](mailto:fjg28@medschl.cam.ac.uk)

**Objectives:** High-grade DCIS (HG DCIS) is associated with upgrade to invasive disease but few studies evaluate the role of MRI in this subset of DCIS. This study compared surgical outcomes of females with HG DCIS on biopsy who had pre-operative MRI with those that proceeded directly to surgery.

**Methods:** This single-centre retrospective, observational study identified patients with pure HG DCIS on pre-operative biopsy from the pathology database. Surgical outcomes, clinicopathological and radiological features were obtained for all patients.

**Results:** From August 2015 to February 2020, 217 patients had HG DCIS on biopsy. Pre-operative MRI was performed in 40 (MRI group) and not in 88 (No MRI group) patients. Initial mastectomy was performed in 25/40 (63%) women in the MRI group and 20/88 (23%)

women in the no MRI group ( $p < 0.0001$ ). No difference was observed in re-operation rate between the two groups, 15% in MRI group vs 22% in No MRI group ( $p = 0.4749$ ). Mean tumour size on histology was larger in mastectomy cases in the MRI group (73.4 mm, range 6–140 mm), than the total MRI group, (58.3 mm, range 0–140 mm) or no MRI group (30.7 mm, range 0–130 mm) ( $p < 0.0001$ ).

**Conclusions:** Pre-operative MRI in HG DCIS is associated with higher mastectomy rates, possibly due to patient selection for MRI, as tumours on final histology were significantly larger. Fewer re-operations were observed in the MRI group although this was not significant.

**Advances in knowledge:** Breast MRI performed pre-operatively in HG DCIS is associated with higher mastectomy rates and fewer re-operation rates.

## INTRODUCTION

Ductal carcinoma *in situ* (DCIS) accounts for approximately 21% of all cases of breast cancer in the UK.<sup>1</sup> Of the three grades of DCIS, high-grade DCIS (HG DCIS) accounts for 51% of cases of screen-detected DCIS, with low- and intermediate-grade DCIS accounting for 18 and 31%, respectively.<sup>2,3</sup> HG DCIS on core biopsy is significantly associated with underestimation of invasive disease at surgical excision compared with low-/intermediate-grade DCIS.<sup>4</sup> A further meta-analysis demonstrated that HG DCIS is a statistically significant prognostic factor associated with subsequent development of invasive breast cancer.<sup>5</sup> In contrast, low- and intermediate-grade DCIS are thought to be biologically less aggressive and thus less likely to proceed to invasive disease. Only 40% of low-grade DCIS progressed to invasive disease 30 years following excision biopsy.<sup>6</sup>

Approximately 20% of females in X undergoing breast conserving surgery (BCS) for breast cancer require re-operation, with up to 30% of females with pure DCIS requiring additional surgery, either re-excision of margins or mastectomy.<sup>7</sup> Further studies also illustrate re-operation rates for DCIS ranging from 29 to 37%.<sup>8,9</sup> This highlights the importance of pre-operative assessment to determine extent of disease. Studies have demonstrated higher sensitivity with pre-operative breast MRI over conventional mammogram for detection of DCIS.<sup>10,11</sup> In addition, breast MRI has a high negative predictive value in excluding an invasive component in patients with a pre-operative diagnosis of DCIS.<sup>12</sup> However, the role of pre-operative breast MRI in the management of pure HG DCIS remains questionable and additional studies have shown no improvement in re-excision or local recurrence rates when MRI is performed pre-operatively in cases of DCIS.<sup>13–15</sup>

The objective of this study was to review all consecutive cases of HG DCIS detected on core or vacuum-assisted biopsy (VAB), to determine those patients that had pre-operative breast MRI performed for further evaluation. We aimed to compare the clinicopathological features of those patients who had breast MRI versus those who did not and to evaluate their outcome in terms of mastectomy and re-operation rates.

## METHODS AND MATERIALS

### Study population

This single institution retrospective study evaluating breast imaging, surgical outcomes and pre and post-operative pathology of HG DCIS cases was approved by the institutional ethics committee. Due to the retrospective nature of the study informed consent was waived. A review of all biopsy results logged in the breast pathology database at X between August 2015 and February 2020 was performed to identify all consecutive females with a B5a (non-invasive) pathology result detected on core or vacuum-assisted biopsy. Each of the results were reviewed to ensure only those females with pure HG DCIS were included. Inclusion criteria were patients over the age of 18 who had a breast biopsy performed (US, stereotactic, MRI guided), with or without pre-operative breast MRI and who underwent breast surgery. Patients from both screening and symptomatic populations were included in the study. Patients excluded from analysis had an invasive component on pre-MRI biopsy, known Pagets disease, pleomorphic lobular carcinoma *in situ* (LCIS), intermediate-grade or low-grade DCIS, a known history of ipsilateral BCS, prior chest wall radiotherapy, or concurrent, contralateral invasive cancer. Cases with incomplete data were also excluded from the analysis.

Positive histological margins at surgery were defined as tumour at ink and close margins as <1 mm for both invasive and *in-situ* disease as per ABS guidelines.<sup>16</sup> Cases were discussed on an individual basis at MDT, regarding the need for further surgery, as in some cases there was no further tissue for re-excision or only small area of focal involvement. Following MDT discussion, an informed decision involving the patient and surgeon was made regarding re-excision or mastectomy.

### Selection of cases for breast MRI

Cases were initially discussed at the breast multidisciplinary meeting, where a decision was taken to perform a pre-operative breast MRI. Indications for MRI included to determine disease extent prior to mastectomy, assessment of occult disease on mammogram that was only visible on US, evaluation prior to attempting BCS, local staging of suspicious or confirmed multifocal DCIS and pre-operative assessment in cases of prior contralateral malignancy. Patients over the age of 18 years undergoing MRI were included in the analysis, with no upper age limit for inclusion. Females with breast densities ranging from BI-RADS a (almost entirely fatty breasts) to d (extremely dense breasts), were included in the study.

### Study groups

Clinicopathological and radiological features were obtained from the X radiological information system (RIS) and patient

archiving and communicating systems (PACS) for each of the patients. Clinical variables included baseline demographics and type of referral (screening or symptomatic). Conventional imaging data recorded included lesion type on mammogram (mass, microcalcifications, distortion, asymmetry), extent of abnormality on mammography and suspicion of multifocality on conventional imaging. Patients were divided into one of two groups, those that had breast MRI performed pre-operatively (MRI group) and those that proceeded directly to surgery (No MRI group).

### MRI acquisition

Breast MRIs were performed on an Optima MR450w 1.5 Tesla MRI scanner (GE Healthcare) with a dedicated 8-Channel phased array breast coil. Following acquisition of the localiser a 2-mm axial  $T_2$  weighted sequence was obtained.  $T_1$ -weighted three-dimensional (3D) fat-saturated (FS) gradient-echo images were initially acquired followed by administration of contrast medium (0.1 mmol/kg Gadobutrol (Bayer)). Six dynamic post-contrast  $T_1$ -weighted 3D FS gradient-echo images were obtained, and subtracted images were generated.

### Image analysis

All breast MRIs were double reported by two breast radiologists with 2–11 years of experience reporting breast MRI. Images were reviewed only at the time of initial clinical interpretation, with evaluation of breast morphology, post contrast enhancement patterns with associated kinetics determined using CADstream (Merge Healthcare Inc.).

## STATISTICAL ANALYSIS

Data were anonymised and entered into a password-protected, electronic spreadsheet using the Excel software programme (Microsoft Corporation). Statistical analysis was performed using GraphPad (online version). Continuous variables are reported as mean and range, with categorical variables reported as frequencies or percent. Differences between MRI and no-MRI groups were assessed via the unpaired t-test for continuous variables and via Fisher's exact test for categorical variables. Differences in histology size between those having initial mastectomy in the MRI group, MRI group and no-MRI groups were assessed via a one-way ANOVA test. A sub-group analysis was performed to compare outcomes of tumour sizes of less than 30 mm compared to greater than 30 mm on conventional imaging in the MRI and No MRI groups.

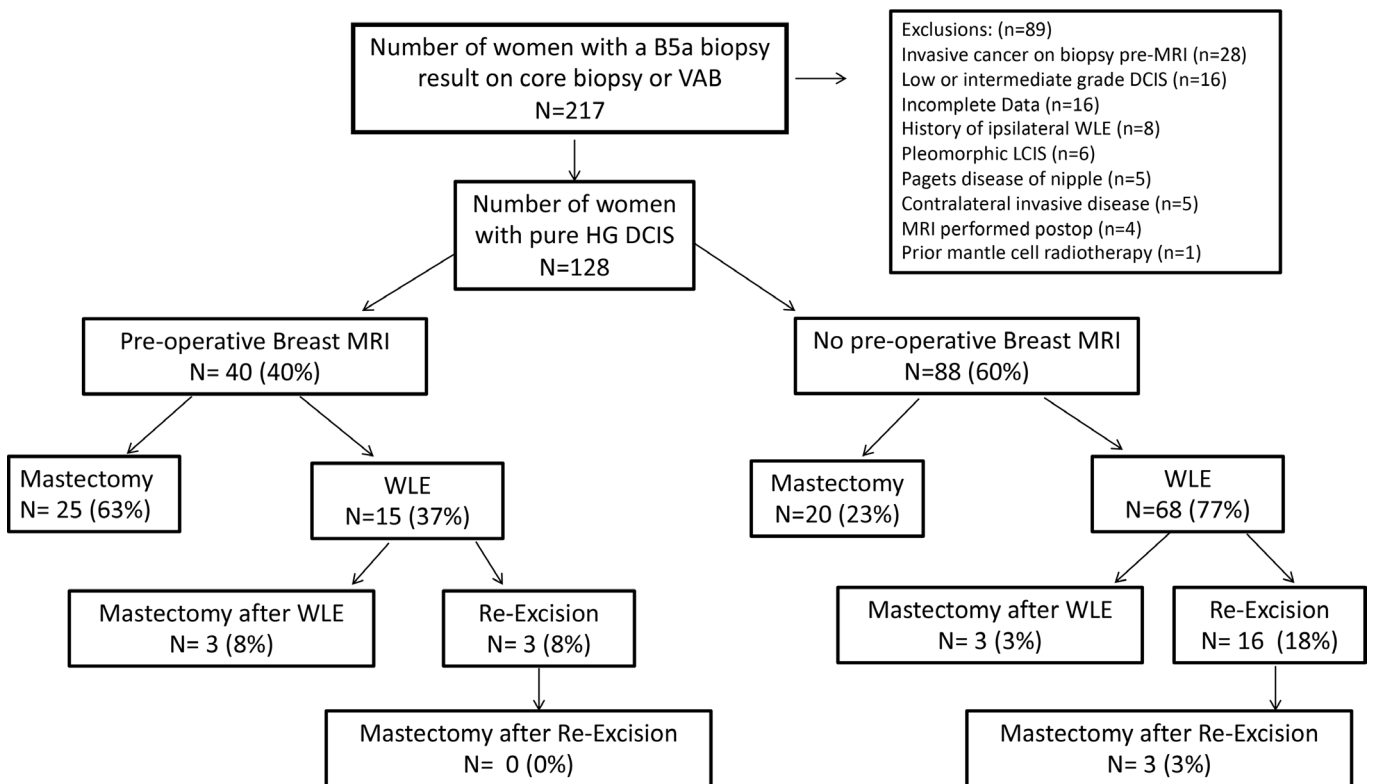
## RESULTS

### Baseline demographics

A total of 217 women had a B5a biopsy result on core or vacuum-assisted biopsy. After review of histology, the electronic patient record and following exclusions, 128 women with pure HG DCIS were eligible for inclusion. Exclusions are detailed in [Figure 1](#). Incomplete data were related to referral to MDT for second opinion from external institution or referral to the X breast unit for further management.

Of the 128 women included in the study, 40 women had a breast MRI performed prior to undergoing surgery (MRI group) and

Figure 1. Flowchart illustrating outcomes of patients with pure HG DCIS detected on core or vacuum biopsy.



88 women proceeded directly to surgery (No MRI group). Baseline demographics of both groups are listed in Table 1. Females in the MRI group were significantly younger when compared with the No MRI group ( $p = 0.0023$ ). There was no difference in mean tumour size on full-field digital mammography (FFDM) between the two groups, with mean size on mammogram 29.40 mm (range 0–90 mm) in the MRI group versus 26.6 mm (0–120 mm) in the No MRI group ( $p = 0.6090$ ). Microcalcifications on mammogram accounted for 70 and 82% of imaging findings in the MRI and No MRI groups, respectively. HG DCIS was occult or not visible on mammogram but detected on ultrasound biopsy in one female in the No MRI group (1%) compared

with five women in the MRI group (12.5%). Invasion on final histology was similar in both groups, with 35% in the MRI group and 27% in the No MRI group ( $p = 0.4080$ ). There was no difference in the overall positive margin rates between the MRI (8/40) and no MRI group (26/88) ( $p = 0.283$ ).

#### Surgical outcomes in the no MRI group

Of the 88 women in the No MRI group, 20 women (23%) had a primary mastectomy and 68 (77%) had an initial BCS performed (Table 2). Of those patients that had BCS, 16 (18%) subsequently underwent re-excision of margins and 3 (3%) underwent

Table 1. Baseline demographics of women with pure HG DCIS detected on core or vacuum assisted biopsy who had preoperative breast MRI performed (MRI group) and those women that proceeded directly to surgery (No MRI group).

	MRI ( $n = 40$ )	No MRI ( $n = 88$ )	P-value
Mean Age (Range)	54.5 years (31- 81)	61.08 years (40-84)	0.0023
Findings on Mammogram			
Calcifications	28 (70%)	72 (82%)	
Mass	5 (12.5%)	12 (14%)	
Distortion	1 (2.5%)	0 (0%)	
Asymmetry	1 (2.5%)	3 (3%)	
Occult	5 (12.5%)	1 (1%)	
Mean Tumour Size on Mammogram (Range)	29.40 mm (0–90 mm)	26.66 mm (0–120 mm)	0.6090
Invasion on Final Histology (n)	14 (35%)	24 (27%)	0.4080
Mean Tumour Size Final Histology (range)	58.35 mm (0–140 mm)	30.72 mm (0–130 mm)	<0.0001

Table 2. Comparison of surgery performed in women who had preoperative breast MRI performed (MRI group) and those women that proceeded directly to surgery (No MRI group).

Parameter	MRI Group NN = 40	No MRI Group NN = 88	P-Value
Initial Mastectomy	25 (63%)	20 (23%)	<0.0001
Wide Local Excision (WLE)	15 (37%)	68 (77%)	<0.0001
Surgery Complete after 1 WLE (one operation)	9/15 (60%)	49/68 (72%)	0.3668
A. Re-excision post WLE (second operation)	3 (5%)	16 (18%)	0.1787
B. Mastectomy post WLE (second operation)	3 (8%)	3 (3%)	0.3757
C. Mastectomy post second WLE (third operation)	0 (0%)	3 (3%)	0.5515
Re-operation Rate (A + B)	6/40 (15%)	19/88 (22%)	0.4749
Final Mastectomy Rate	28 (70%)	26 (30%)	<0.0001

mastectomy for management of positive margins on histology. This indicates a 19/88 (22%) re-operation rate. Of those that had re-excision of margins three women (3%) ultimately went on to have a mastectomy. The surgical outcomes for this group are summarised in [Figure 1](#). Overall, 26 women (30%) in the No MRI group had a mastectomy performed.

#### Surgical outcomes in the MRI group

In the MRI group ( $n = 40$ ), 25 women (63%) had initial mastectomy performed while the remaining 15 women (37%) underwent BCS ([Table 2](#)). In 9 of these 15 (60%), surgery was complete after one operation. A further three women underwent a re-excision of margins and the remaining 3 women were referred for completion mastectomy. This generates a re-operation rate of 6/40 (15%). Biopsy following breast MRI was performed in seven women (17.5%), with bilateral lesions biopsied in one case and MRI guided biopsy performed for evaluation of five of the eight areas of additional abnormality. HG DCIS was present in two of the biopsies, with B3 result in two and the remaining four were benign. The MRI group had an overall mastectomy rate of 28/40 (70%). The surgical outcomes for this group are summarised in [Figure 1](#).

#### Evaluation of the mastectomy cases in the MRI group

Reviewing the 28 women who underwent mastectomy in the MRI group in more detail, these females had a lower mean age of 51.2 years (range 32–78) when compared with the MRI group (mean age 54.5 years). Tumour size on mammogram was larger

in those females who underwent mastectomy in the MRI group, mean 34.4 mm (0–90 mm), compared with 29.4 mm (range 0–90 mm) in all cases the MRI group and 26.6 mm (0–120 mm) in the No MRI group. Nine of the 28 women (32%) had invasive disease on final histology. Mean tumour size on histology was significantly larger in those females who underwent mastectomy in the MRI group (73.3 mm, range 6–140 mm), than the total MRI group, (58.3 mm, range 0–140 mm) or the No MRI group (30.7 mm, range 0–130 mm) ( $p < 0.0001$ ). In 17/25 (68%) women that underwent initial mastectomy in the MRI group, a decision was taken to proceed to mastectomy prior breast MRI, with MRI acting as an aid to strengthen decision making. In the majority (20/25) of cases the decision to perform MRI was based on MDT discussion. While most mastectomies were performed in 22/25 women for extensive disease, three women opted for mastectomy due to personal choice rather than undergoing the MDT recommended BCS. Bilateral mastectomy was performed in four women, with known pre-operative contralateral HG DCIS in one of these females and the other three undergoing contralateral risk reducing mastectomy, due to concerns about future recurrence based on age ( $n = 1$ ) and to maintain symmetry ( $n = 2$ ).

#### Comparison of surgical outcomes of tumour size less than or greater than 30 mm

In line with published literature (see discussion) a sub-group analysis was performed to compare outcomes of tumour sizes of less than 30 mm compared to greater than 30 mm on conventional imaging in the MRI and No MRI groups ([Table 3](#)). No

Table 3. Comparison of surgery performed in women with tumours less than or greater than 30mm on mammogram or ultrasound in MRI group and No MRI group

Parameter	Tumour Size > 30 mm			Tumour Size < 30 mm		
	MRI Group N = 18	No MRI Group N = 28	P Value	MRI Group N = 22	No MRI Group N = 60	P Value
Mastectomy	14 (78%)	16 (57%)	0.2099	11 (50%)	4 (7%)	0.00001
Wide local excision	4 (22%)	12 (43%)	0.2099	11 (50%)	56 (93%)	0.00001
Re-excision	2 (11%)	5 (18%)	0.6879	1 (5%)	11 (18%)	0.1646
Re-intervention post WLE	3 (17%)	5 (18%)	1.000	3 (14%)	17 (28%)	0.2477
Final Mastectomy Rate	15 (83%)	16 (57%)	0.1068	13 (60%)	10 (17%)	0.0005

difference was observed in initial mastectomy rate, re-excision or re-operation rates and overall mastectomy rates in females with tumours on conventional imaging greater than 30 mm in the MRI and No MRI groups. A higher mastectomy rate was observed in females with tumours < 30 mm on conventional imaging in the MRI group. No difference was observed in re-excision or re-operation rate between the two groups in tumours < 30 mm.

Post-treatment surveillance consisting of annual mammogram for 5 years is ongoing in this cohort of patients. Although surveillance is incomplete, to date there has been local recurrence in the ipsilateral breast in one patient in the MRI group (invasive NST following mastectomy) and in five patients in the No MRI group (three patients with both invasive and in situ disease and two with high-grade DCIS alone all following WLE).

## DISCUSSION

This retrospective observational study of clinical practice at a single centre illustrates that pre-operative breast MRI was undertaken in 68% of cases where the decision had already been taken to perform a mastectomy. Pre-operative breast MRI was associated with both higher initial and overall mastectomy rates. There was slightly lower re-operation (re-excision and subsequent mastectomy) rates in the MRI group when compared with no pre-operative breast MRI (15% v 22%) but this was not statistically significant. The concern in the management of HG DCIS is the increased likelihood of local recurrence and invasive disease in a shorter timeframe compared to intermediate or low-grade DCIS. However, given the relatively high cost and low specificity associated with breast MRI, its exact role in evaluation of DCIS remains questionable and few studies of pre-operative breast MRI have separated HG DCIS from low- and intermediate-grade DCIS.

A meta-analysis of nine studies, including 1077 patients with DCIS who had pre-operative MRI performed and 2175 with DCIS that did not, showed no significant difference in positive margins or re-excision rates following breast-conserving surgery.<sup>13</sup> While overall mastectomy rates were similar between the two groups, having a pre-operative MRI performed significantly increased a

female's odds of undergoing an initial mastectomy. This meta-analysis included only two randomised-controlled trials, with both containing small numbers.<sup>17,18</sup> In our study, pre-operative breast MRI had a significantly higher initial mastectomy rate, but also a higher overall mastectomy rate.

Balleyguier et al performed a multicentre, randomised controlled trial, only including patients with DCIS up to 30 mm on conventional imaging, comparing MRI or No MRI prior to surgery on re-intervention rates.<sup>19</sup> Although there was a trend to lower re-operation rates in the MRI group in an intention-to-treat analysis no significant difference was observed (20% vs 27%,  $p = 0.13$ ). This is similar to our study (15% re-vs 22%  $p = 0.4749$ ). In their study the initial mastectomy rate was low in both groups, due to the study inclusion criteria of tumours < 30 mm on initial imaging, but was slightly higher in the MRI group (9% vs 4%). No difference was observed in overall mastectomy rates between the two groups. Results were not analysed comparing HG DCIS with intermediate and low-grade DCIS. When we performed a subgroup analysis of tumours < 30 mm on conventional imaging we detected higher initial and overall mastectomy rates in the MRI group with no difference in re-excision or re-intervention between both groups although numbers in the subgroup analysis were small. In tumours > 30 mm we observed no difference in mastectomy rates or re-intervention between the two groups.

In a retrospective population-based review of the Netherlands Cancer registry to examine clinical practice, breast MRI was performed pre-operatively in 2,382 of 10,415 cases of DCIS (22.9%).<sup>20</sup> Similar to our study, this group found that pre-operative breast MRI was more likely to be performed in a younger group of females. Initial mastectomy rates (45% vs 24.4%) and overall mastectomy rates (51.4% vs 30%) were higher in the MRI group than the No MRI group, which also agree with our findings.

Table 4 is a summary of recently published studies comparing surgical outcomes of females undergoing pre-operative MRI versus those females proceeding directly to surgery. Most studies illustrate an increase in initial and overall mastectomy rates in

Table 4. Summary of published studies comparing surgical outcomes in women undergoing pre-operative breast MRI versus those with no pre-operative breast MRI in DCIS

Author, Year	Type of Study	DCIS included	No. of patients MRI	No. of patients No MRI	MRI vs No MRI			Change in management based on MRI
					Initial Mastectomy	Re-excision rate	Overall mastectomy	
Fancellu et al <sup>13</sup> 2015	Meta-analysis	All DCIS	1077	2175	27.6vs 18.2% ( $p = 0.012$ )	41.6vs 40.1% ( $p = 0.759$ )	13.9 vs 11.5% ( $p = 0.340$ )	15.7%
Balleyguier et al <sup>19</sup> 2019	Randomised controlled trial	DCIS < 30 mm on imaging	178	174	9vs 4% ( $p = 0.06$ )	20vs 27% ( $p = 0.13$ )	18vs 17% ( $p = 0.93$ )	NA
Yoon et al <sup>21</sup> 2020	Retrospective cohort comparison	All DCIS	430	111	37.7vs 34.0% ( $p = 0.59$ )	4.2vs 14.7% ( $p = 0.03$ )	38.7vs 40.6% ( $p = 0.79$ )	13%
Keymeulen et al <sup>20</sup> 2019	Retrospective population based	All DCIS	2382	8033	45.3vs 24.4% OR 2.22 (95% CI 2.00–2.45)	21.0vs 16.7% OR 1.17 (95% CI 1.00–1.37)	51.4vs 30% OR 2.11 (95% CI 1.91–2.33)	NA

those having pre-operative breast MRI, with little change in re-excision rate between the two groups. A single study demonstrates an increase in re-operation rate with no change in mastectomy rates.<sup>21</sup> Only one of the studies listed is a randomised controlled trial and this study limited its inclusion criteria to DCIS < 30 mm on conventional imaging. The mastectomy rates in our study are higher than recently published data but this may be due to the small patient number and patient selection for breast MRI. In the majority of cases the decision to perform mastectomy had been made prior to MRI.

Few studies review the outcomes of pure HG DCIS, and instead include all grades of *in situ* disease. Keymeulen et al compared low-grade DCIS with intermediate-/high-grade DCIS but found no difference between the two groups for re-operation, initial or overall mastectomy rates.<sup>20</sup> In a further study of 154 cases of pure HG DCIS, Hajaj et al found higher initial mastectomy rates in the MRI group (51% vs 4%) with higher re-operation (re-excision or completion mastectomy) rates in those with not undergoing pre-operative breast MRI (26% vs 8%).<sup>22</sup>

MRI may prove useful in detection of additional disease and act as a tool to aid surgical management. Yoon et al identified 67 additional lesions (16%) on MRI, of which 25 (37%) were malignant.<sup>21</sup> A recent study by Lamb et al which reviewed 963 women with pure DCIS, 236 of whom underwent breast MRI.<sup>23</sup> Of these, 28% had an abnormality on breast MRI that required further work-up/biopsy. Additional disease was detected pre-operatively in 11% of patients on biopsy, 50% with an invasive component. A further study by Taskin et al shows the benefit of breast MRI in evaluation of suspicious mammographic microcalcifications, with abnormal enhancement detected on MRI in 88% of cases, with the MRI negative cases proving to be low- or intermediate-grade DCIS.<sup>24</sup> In our study, biopsy following breast MRI was performed in seven women (17.5%) for evaluation of eight MRI-detected lesions, MRI-guided biopsy performed for evaluation of 5/8 of the lesions. The cancer detection rate with MRI biopsy of 5% (2/40) was lower in our study, which may be related to the lower number of patients and high initial mastectomy rate. The requirement for additional biopsy, in particular MRI biopsy, adds to the cost of this already relatively expensive imaging tool.

Our study has a number of limitations. It is a single centre, retrospective observational study with small numbers of pure HG DCIS, with only a small subset of these patients undergoing breast MRI. While all consecutive cases of HG DCIS were reviewed, the cases were not matched controls and differences

were observed between the MRI and No MRI groups in terms of patient age and initial presentation, reflective of multidisciplinary decision for referral for preoperative breast MRI.

It is well established that family history is a risk factor for development of HG DCIS, and in addition, family history in the presence of DCIS is a risk factor for invasive disease.<sup>25–27</sup> However, in the current study family history was not taken into consideration when referring patients with DCIS for breast MRI, as the majority were screening cases with details regarding family history unavailable at the time of MDT. All patients with newly diagnosed HG DCIS at our institution are recommended to have MRI prior to surgery. At institutions where there is limited access to MRI or there is selective use of MRI in cases of DCIS, reviewing family history at MDT could prove useful when recommending patients for breast MRI.

In summary, recently published studies show an increase in initial and overall mastectomy rates, with little change in re-excision rates between those having MRI performed pre-operatively compared with patients proceeding directly to surgery in cases of HG DCIS. Over recent years it has been our practice to actively perform breast MRI in all females with HG DCIS prior to surgery as per MDT discussion, to help aid surgical decision. With larger tumours on conventional imaging, at the upper limits of breast conservation, breast MRI can improve diagnostic confidence in the extent of the DCIS and so reassure the surgeon and patient that mastectomy is the best oncological option. Based on our findings and those of recently published studies, we believe in cases with initially confirmed or suspected extensive radiological disease that pre-operative breast MRI is requested to confirm disease extent in those destined for mastectomy. In those with patients with less than 30 mm of disease on mammography, further studies evaluating pre-operative MRI are required, as there appears to be a trend towards reduced re-operation rates. Collection of national data from breast screening, inclusive of all tumour sizes of HG DCIS, may help fully delineate the impact of MRI on surgical outcomes of HG DCIS, given that this group of patients are most in need of accurate surgical management.

## ACKNOWLEDGEMENTS

This work was supported by the NIHR Cambridge BRC (BRC-1215-20014). The views expressed are those of the author and not necessarily those of the NIHR or the UK Department of Health and Social Care.

## REFERENCES

1. Breast Screening Programme. Report. England. 2018. Available from: <https://digital.nhs.uk/data-and-information/publications/statistical/breast-screening-programme/england--2018-19>
2. Consensus conference on the classification of ductal carcinoma in situ. the consensus conference committee. *Cancer* 1997; **80**: 1798–1802. [https://doi.org/10.1002/\(sici\)1097-0142\(19971101\)80:9<1798::aid-cnrcr15>3.0.co;2-0](https://doi.org/10.1002/(sici)1097-0142(19971101)80:9<1798::aid-cnrcr15>3.0.co;2-0)
3. van Luijt PA, Heijnsdijk EAM, Fracheboud J, Overbeek LIH, Broeders MJM, Wesseling J, et al. The distribution of ductal carcinoma in situ (DCIS) grade in 4232 women and its impact on overdiagnosis in breast cancer screening. *Breast Cancer Res* 2016; **18**: 47. <https://doi.org/10.1186/s13058-016-0705-5>
4. Brennan ME, Turner RM, Ciatto S, Marinovich ML, French JR, Macaskill P, et al. Ductal carcinoma in situ at core-needle

- biopsy: meta-analysis of underestimation and predictors of invasive breast cancer. *Radiology* 2011; **260**: 119–28. <https://doi.org/10.1148/radiol.11102368>
5. Visser LL, Groen EJ, van Leeuwen FE, Lips EH, Schmidt MK, Wesseling J. Predictors of an invasive breast cancer recurrence after DCIS: A systematic review and meta-analyses. *Cancer Epidemiol Biomarkers Prev* 2019; **28**: 835–45. <https://doi.org/10.1158/1055-9965.EPI-18-0976>
  6. Sanders ME, Schuyler PA, Dupont WD, Page DL. The natural history of low-grade ductal carcinoma in situ of the breast in women treated by biopsy only revealed over 30 years of long-term follow-up. *Cancer* 2005; **103**: 2481–84. <https://doi.org/10.1002/cncr.21069>
  7. Jeevan R, Cromwell DA, Trivella M, Lawrence G, Kearins O, Pereira J, et al. Reoperation rates after breast conserving surgery for breast cancer among women in England: retrospective study of hospital episode statistics. *BMJ* 2012; **345**: e4505bmj. e4505. <https://doi.org/10.1136/bmj.e4505>
  8. Bani MR, Lux MP, Heusinger K, Wenkel E, Magener A, Schulz-Wendland R, et al. Factors correlating with reexcision after breast-conserving therapy. *Eur J Surg Oncol* 2009; **35**: 32–37. <https://doi.org/10.1016/j.ejso.2008.04.008>
  9. Langhans L, Jensen M-B, Talman M-LM, Vejborg I, Kroman N, Tvedskov TE. Reoperation rates in ductal carcinoma in situ vs invasive breast cancer after wire-guided breast-conserving surgery. *JAMA Surg* 2017; **152**: 378–84. <https://doi.org/10.1001/jamasurg.2016.4751>
  10. Kuhl CK, Schrading S, Bieling HB, Wardelmann E, Leutner CC, Koenig R, et al. MRI for diagnosis of pure ductal carcinoma in situ: A prospective observational study. *Lancet* 2007; **370**: 485–92. [https://doi.org/10.1016/S0140-6736\(07\)61232-X](https://doi.org/10.1016/S0140-6736(07)61232-X)
  11. Baur A, Bahrs SD, Speck S, Wietek BM, Krämer B, Vogel U, et al. Breast MRI of pure ductal carcinoma in situ: sensitivity of diagnosis and influence of lesion characteristics. *Eur J Radiol* 2013; **82**: S0720-048X(13)00237-4: 1731–37. <https://doi.org/10.1016/j.ejrad.2013.05.002>
  12. Deurloo EE, Sriram JD, Teertstra HJ, Loo CE, Wesseling J, Rutgers EJT, et al. MRI of the breast in patients with DCIS to exclude the presence of invasive disease. *Eur Radiol* 2012; **22**: 1504–11. <https://doi.org/10.1007/s00330-012-2394-5>
  13. Fancellu A, Turner RM, Dixon JM, Pinna A, Cottu P, Houssami N. Meta-analysis of the effect of preoperative breast MRI on the surgical management of ductal carcinoma in situ. *Br J Surg* 2015; **102**: 883–93. <https://doi.org/10.1002/bjs.9797>
  14. Davis KL, Barth RJ Jr, Gui J, Dann E, Eisenberg B, Rosenkranz K. Use of MRI in preoperative planning for women with newly diagnosed DCIS: risk or benefit? *Ann Surg Oncol* 2012; **19**: 3270–74. <https://doi.org/10.1245/s10434-012-2548-3>
  15. Pilewskie M, Olcese C, Eaton A, Patil S, Morris E, Morrow M, et al. Perioperative breast MRI is not associated with lower locoregional recurrence rates in DCIS patients treated with or without radiation. *Ann Surg Oncol* 2014; **21**: 1552–60. <https://doi.org/10.1245/s10434-013-3424-5>
  16. Association of Breast Surgery ABS Consensus Margin Width in Breast Conservation Surgery 2015. [www.associationofbreastsurgery.org.uk](http://www.associationofbreastsurgery.org.uk)
  17. Turnbull L, Brown S, Harvey I, et al. (2010) Comparative effectiveness of MRI in breast cancer (COMICE) trial: A randomised controlled trial. *Lancet* 375:563-571
  18. Peters NHGM, van Esser S, van den Bosch MAAJ, Storm RK, Plaisier PW, van Dalen T, et al. Preoperative MRI and surgical management in patients with nonpalpable breast cancer: the MONET – randomised controlled trial. *European Journal of Cancer* 2011; **47**: 879–86. <https://doi.org/10.1016/j.ejca.2010.11.035>
  19. Balleyguier C, Dunant A, Ceugnart L, Kandel M, Chauvet M-P, Chérel P, et al. Preoperative breast magnetic resonance imaging in women with local ductal carcinoma in situ to optimize surgical outcomes: results from the randomized phase III trial IRCIS. *JCO* 2019; **37**: 885–92. <https://doi.org/10.1200/JCO.18.00595>
  20. Keymeulen KBIM, Geurts SME, Lobbes MBI, Heuts EM, Duijm LEM, Kooreman LFS, et al. population-based study of the effect of preoperative breast MRI on the surgical management of ductal carcinoma in situ. *Br J Surg* 2019; **106**: 1488–94. <https://doi.org/10.1002/bjs.11299>
  21. Yoon GY, Choi WJ, Kim HH, Cha JH, Shin HJ, Chae EY. Surgical outcomes for ductal carcinoma in situ: impact of preoperative MRI. *Radiology* 2020; **295**: 296–303. <https://doi.org/10.1148/radiol.2020191535>
  22. Hajaj M, Karim A, Pascaline S, Noor L, Patel S, Dakka M. Impact of MRI on high grade ductal carcinoma insitu (HG DCIS) management, are we using the full scope of MRI? *Eur J Radiol* 2017; **95**: S0720-048X(17)30347-9: 271–77. <https://doi.org/10.1016/j.ejrad.2017.08.027>
  23. Lamb LR, Oseni TO, Lehman CD, Bahl M. Pre-operative MRI in patients with ductal carcinoma in situ: is MRI useful for identifying additional disease? *Eur J Radiol* 2020; **129**: S0720-048X(20)30319-3: 109130. <https://doi.org/10.1016/j.ejrad.2020.109130>
  24. Taskin F, Kalayci CB, Tuncbilek N, Soydemir E, Kurt N, Kaya H, et al. The value of MRI contrast enhancement in biopsy decision of suspicious mammographic microcalcifications: a prospective multicenter study. *Eur Radiol* 2021; **31**: 1718–26. <https://doi.org/10.1007/s00330-020-07265-y>
  25. Peila R, Arthur R, Rohan TE. Risk factors for ductal carcinoma in situ of the breast in the UK biobank cohort study. *Cancer Epidemiol* 2020; **64**: S1877-7821(19)30158-4: 101648. <https://doi.org/10.1016/j.canep.2019.101648>
  26. Lamb LR, Kim G, Oseni TO, Bahl M. Noncalcified ductal carcinoma in situ (DCIS): rate and predictors of upgrade to invasive carcinoma. *Acad Radiol* 2021; **28**: S1076-6332(20)30097-0: e71–76. <https://doi.org/10.1016/j.acra.2020.02.011>
  27. Reeves GK, Pirie K, Green J, Bull D, Beral V, Million Women Study Collaborators. Comparison of the effects of genetic and environmental risk factors on in situ and invasive ductal breast cancer. *Int J Cancer* 2012; **131**: 930–37. <https://doi.org/10.1002/ijc.26460>